



GREYHOUND HEALTH AND WELLNESS QUARTERLY



THE OHIO STATE UNIVERSITY
COLLEGE OF VETERINARY MEDICINE

By Liliana Marin & Guillermo Couto



G
R
E
Y
H
O
U
N
D
S

GREYHOUND ORAL HEALTH

Why do some Greyhounds have gingivitis, even though owners do all that they can to maintain their dental hygiene?

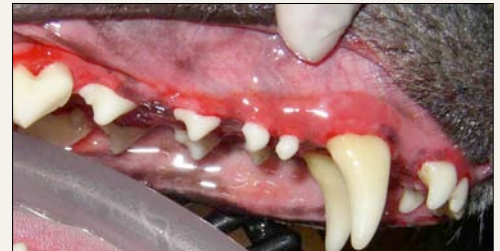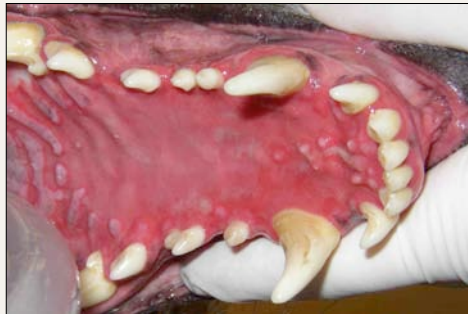Several oral diseases are associated with reddening of the gum over the crown of the tooth; they include mild to severe gingivitis (inflammation of the gums), mild to severe periodontal disease, and halitosis (bad breath).

The most common cause of gingivitis not associated with dental disease in Greyhounds at The Ohio State Veterinary Hospital is lymphoplasmacytic stomatitis (LPS), a common immune-mediated inflammatory condition; however, other possibilities include: pemphigus vulgaris, bullous pemphigoid, and systemic lupus erythematosus (SLE).

A biopsy is needed to confirm the diagnosis and to institute the correct treatment.

Lymphoplasmacytic stomatitis (LPS) is fairly easy to manage with immunosuppressive drugs.

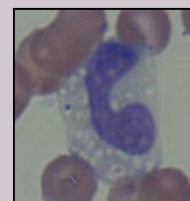
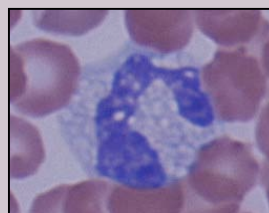
Most hounds with LPS can be treated with azathioprine (50 mg PO q24h for a week, then 50 mg q48h), with or without corticosteroids, with good results.



Pictures provided by Dr. Dwight Ridenour.

DID YOU KNOW?

Some healthy Greyhounds have “vacuolated” eosinophils. (I.e., eosinophils with empty, non-staining granules). Vacuolated eosinophils resemble toxic neutrophils or vacuolated monocytes; and can make accurate identification difficult for veterinarians and technicians who are not familiar with the hematologic idiosyncrasies of the breed.



GREYHOUNDS



SURVIVORS

Thousands of Greyhounds are killed when their racing careers end. Many adoption groups around the US and Europe, work very hard every day to find a warm and safe home where they can spend the rest of their lives.

These Greyhounds deserve the opportunity to be loved by people that appreciate this spectacular breed.

We call these Greyhounds survivors, because they have lived very difficult lives; and they have had the strong will to “survive” unfavorable conditions.

Every year the adoption group ***Greyhound Adoption of Ohio*** celebrates ***Hike For Hounds***, an outdoor fundraiser, where the proceeds from the walks are used to provide medical, dental, and kennel care for retired racing Greyhounds.



Pictures from “Hike for Hounds 2007.”

Top Right: Linda Perko,
Director of Greyhound Adoption of OH.
<http://www.greyhoundadoptionofoh.org/>

These 2 beautiful girls (Hannah and Ruthie) were brought from Juarez, Mexico in 2005. They now are part of a wonderful family.

There are hundreds of Greyhounds like them, waiting for a home. If you would like to find a Greyhound Adoption Group near you, please visit:

<http://www.skhuckelservices.com/gg/adoptiongroups.asp>



Dr. Couto, has been volunteering at a Galgo (Spanish Greyhound) Shelter in Medina del Campo-Spain (Scooby Medina) for several years. Scooby is an organization that has rescued Galgos in Spain since 1977.

The number of rescued Galgos has grown through the years. A total of 827 dogs (90% Galgos) were saved during 2004. This year (June, 2007), Dr. Couto traveled with a group of OSU students and volunteer clinicians to Scooby Medina; where they spayed and neutered dogs, and provide preventive health care (shelter medicine). See more in the next issue of the Newsletter.

Left Top: Some of the wonderful people who volunteer in Scooby Medina.

Left Bottom: Some of the rescued Galgos.

http://www.scoobymedina.com/home_en.htm

Greyhound books

- *The Reign of the Greyhound.*

Branigan, Cynthia A. A Popular History of the Oldest Family of Dogs, 2nd ed. Hoboken, NJ: Howell Book House: Wiley Publishing Inc., 2004.

- *Retired Racing Greyhounds for Dummies.*

Livingood, Lee. New York: Hungry Minds, Inc., 2000.

- *The Ultimate Greyhound.*

Sullivan, Mark, ed. Gloucestershire, UK: Howell Book House: IDG Books Worldwide, Inc.: Ringpress Books, 1999.

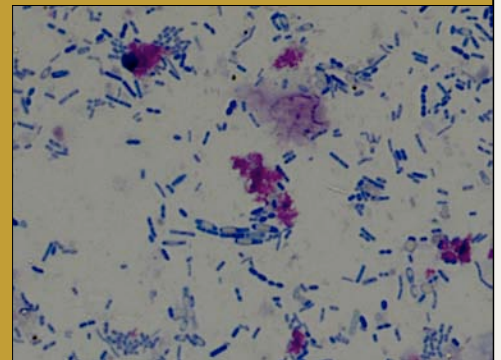


WHAT IS YOUR DIAGNOSIS?

Clinical Signs:

Six-year-old, male castrated Greyhound, admitted to the Greyhound Health and Wellness Clinic, with a 3-day history of large bowel diarrhea. No changes in food, and no previous diseases.

Fecal Smear slide →



1. WHAT IS YOUR FECAL SMEAR DESCRIPTION?
2. WHAT IS YOUR DIAGNOSIS?
3. WHAT ARE YOUR TREATMENT OPTIONS?

1. Canine feces, stained with Diff-Quik. Numerous spores are seen as clear vacuoles in darkly staining vegetative cells.
2. Clostridium overgrow.
3. First option: Metronidazol, PO 15-25mg/kg twice a day for 5-10 days.
Second option: Tylosin, PO 20 to 80 mg/kg/day divided twice a day for 5 days.
Some dogs need long-term therapy.

SOME CURRENT OSU GREYHOUND STUDIES

- Thromboelastography (TEG) to detect fibrinolytic abnormalities in retired racing Greyhounds with postoperative bleeding.
- Artemisinin in retired racing Greyhounds with appendicular osteosarcoma.
- Renal lesions associated with proteinuria in retired racing Greyhounds.



How to Contribute...We depend on your generosity.

To make a donation to support the Greyhound Health and Wellness Program. Please Contact Dr. C. Guillermo Couto (couto.1@osu.edu), or Karen Longbrake, Director of Development at (614) 688-8433 or mailto:longbrake.1@osu.edu. We thank you very much for your generous support so that we may continue our mission to help the Greyhounds.